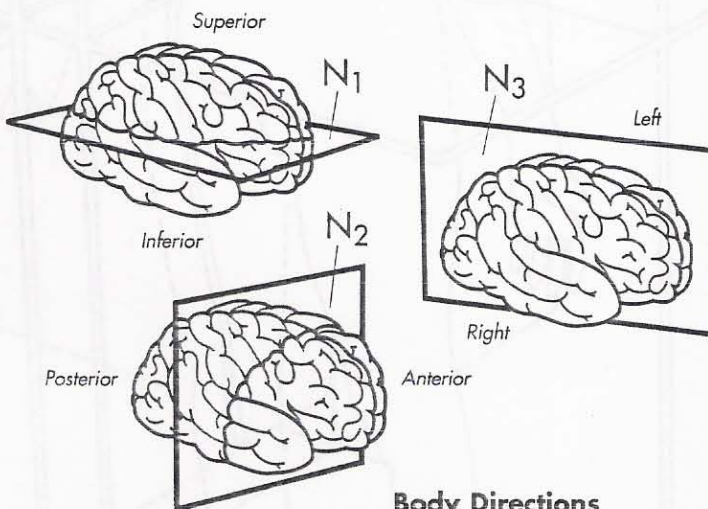
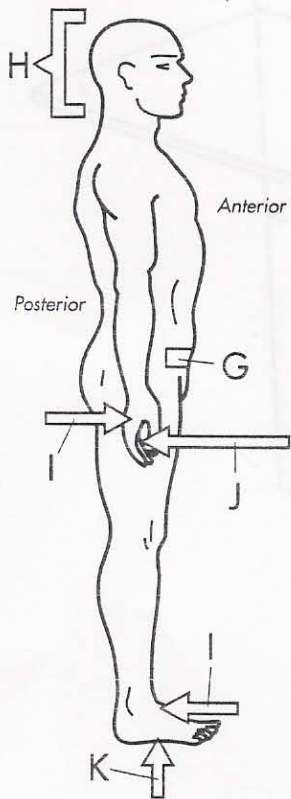
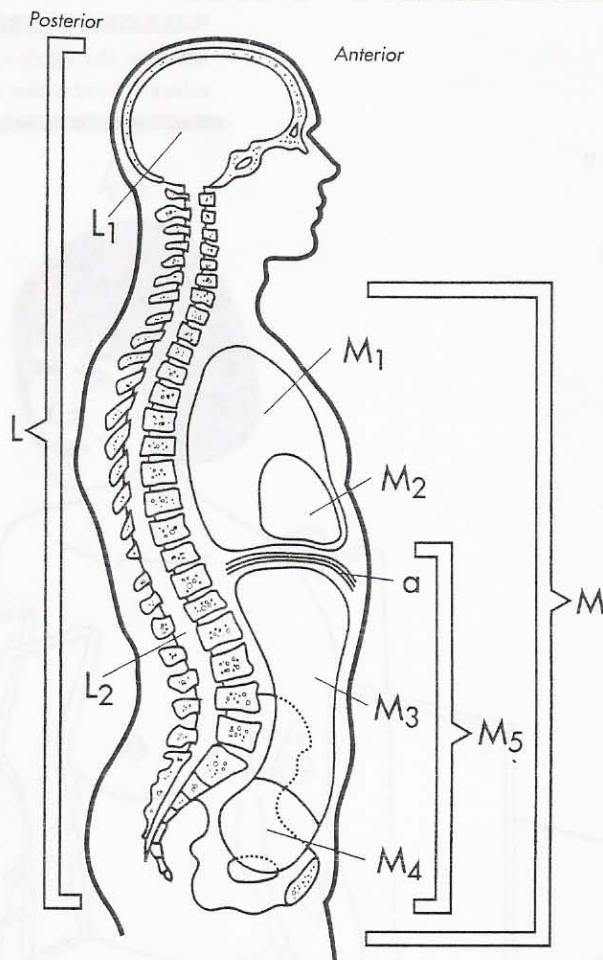
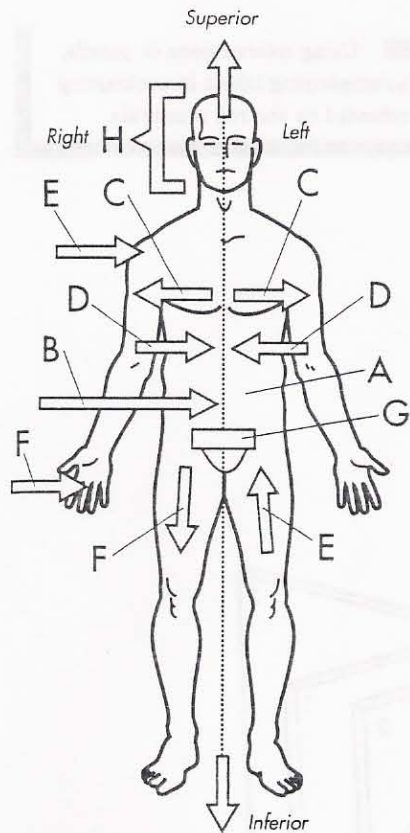


# ANATOMICAL TERMINOLOGY



## Body Directions

- Anatomical position A ○
- Midline B ○
- Lateral C ○
- Medial D ○
- Proximal E ○
- Distal F ○
- Caudal G ○

- Cranial H ○
- Dorsal surface I ○
- Palmar surface J ○
- Plantar surface K ○
- Diaphragm a ○

## Body Cavities

- Dorsal cavity L ○
- Cranial cavity L<sub>1</sub> ○
- Spinal cavity L<sub>2</sub> ○
- Ventral cavity M ○
- Thoracic cavity M<sub>1</sub> ○
- Pericardial cavity M<sub>2</sub> ○
- Abdominal cavity M<sub>3</sub> ○
- Pelvic cavity M<sub>4</sub> ○
- Abdominopelvic cavity M<sub>5</sub> ○

## Planes

- Transverse plane N<sub>1</sub> ○
- Frontal plane N<sub>2</sub> ○
- Sagittal plane N<sub>3</sub> ○